



# IMAGE OF THE MONTH

**10/2021**

## FROM YOUNG ESPGHAN

**Benno Kohlmaier, Mona Schneider,  
Manfred Modl, Andrea Deutschmann**  
*Medical University of Graz, Austria*

**Wolf-Dietrich Huber**  
*Medical University of Vienna, Austria*

Benno Kohlmaier<sup>1</sup>, Mona Schneider<sup>2</sup>, Wolf-Dietrich Huber<sup>3</sup>, Manfred Modl<sup>4</sup>, Andrea Deutschmann<sup>1</sup>

1 Clinical department of general paediatrics, university clinic of paediatrics, Medical University of Graz

2 University ophthalmic clinic, Medical University of Graz

3 Clinical department of pediatric nephrology and gastroenterology, university clinic of paediatrics, Medical University of Vienna

4 Clinical department of pediatric pulmonology and allergology, university clinic of paediatrics, Medical University of Graz

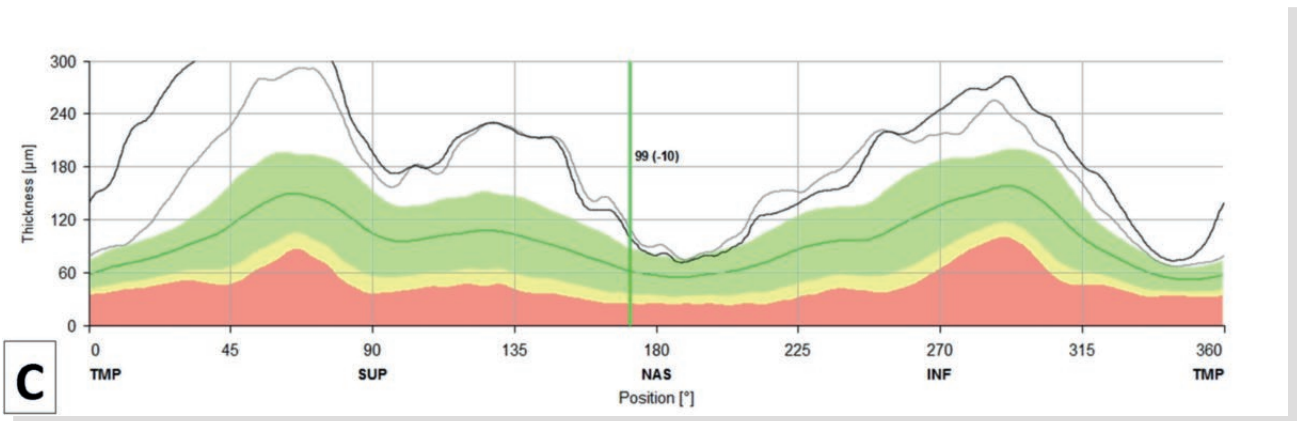
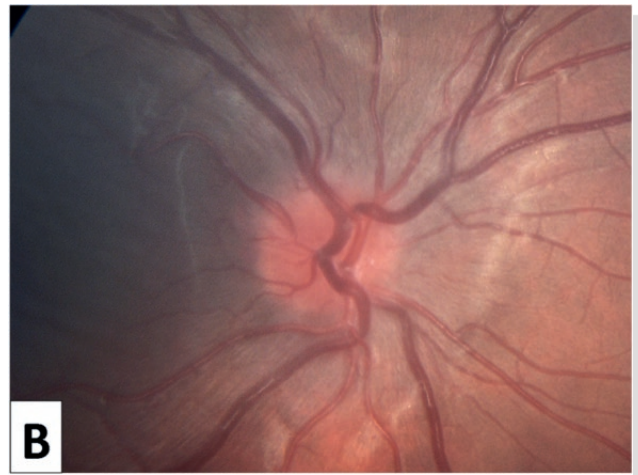
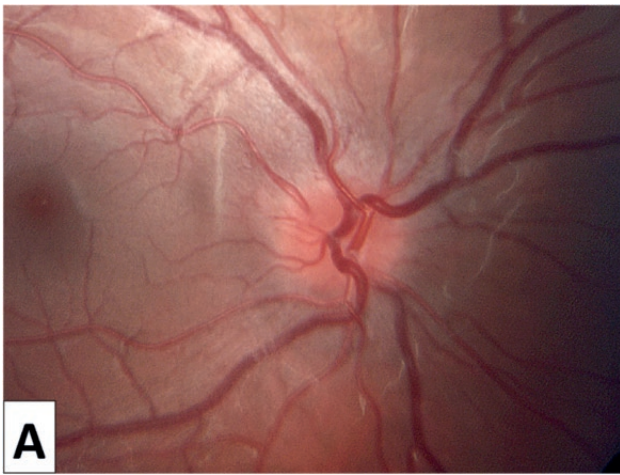### Double-sided papilledema with normal intracranial pressure after liver transplantation

A 15-year-old girl with cystic fibrosis related liver disease (Child B, albumine 2.7 g/dl, PT 35%) with hepatopulmonary syndrome, portal hypertension and oesophageal varices graded II-III was listed for isolated liver transplantation (LTx). Pretransplant an intravitreal haemorrhage of her left eye was found which resolved after successful LTx. Immunosuppression consisted of cyclosporine and steroids. Surprisingly, ophthalmologic control showed papilledema of both eyes confirmed by optical coherence tomography (OCT).

The girl didn't report any symptoms such as headache or blurred vision. Cerebral magnet resonance imaging and lumbar puncture with measurement of the cerebrospinal fluid pressure (5 mmHg) ruled out typical reasons for papilledema.

As papilledema increased with a progredient loss of vision the following weeks, immunosuppression was changed to tacrolimus. Papilledema resolved with improvement of her vision. Double-sided papilledema with normal intracranial pressure is a rare condition. According to Friedman et al. this constellation is called probable "normal pressure" pseudotumor cerebri syndrome. (1)

The immune-suppressant ciclosporine can be a very rare reason for pseudotumor cerebri. (2–5)



### Pictures:

- A) Papilledema in fundoscopy of the right eye.
- B) regression of papilledema of the right eye three month later.
- C) measuring of retinal nerve fibre layer using OCT (optical coherence tomography) confirms the diagnosis of papilledema of the right eye.

### References:

1. Friedman DI, Liu GT, Digre KB. Revised diagnostic criteria for the pseudotumor cerebri syndrome in adults and children. *Neurology*. 2013 Sep 24;81(13):1159–65.
2. Costa KM a H, Almeida JB De, Félix RHDM, Silva Júnior MF Da. [Pseudotumor cerebri associated with cyclosporin use following renal transplantation]. *J Bras Nefrol órgão Of Soc Bras e Latino-Americana Nefrol*. 2010;32(1):136–9.
3. Saito J, Kami M, Taniguchi F, Kanda Y, Takeda N, Mitani K, et al. Unilateral papilledema after bone marrow transplantation. *Bone Marrow Transpl*. 1999;23(9):963–5.
4. Orpin S, Ilyas SU. A potentially rare and serious consequence of ciclosporin therapy for psoriasis. *Clin Exp Dermatol [Internet]*. 2014 Dec;39(8):947–8.
5. Blasco Morente G, Tercedor Sánchez J, Garrido Colmenero C, Martínez García E, Molina-Carballo A. Pseudotumor cerebri associated with cyclosporine use in severe atopic dermatitis. *Pediatr Dermatol*. 2015;32(2):237–9.