



IMAGE OF THE MONTH

10/2020

FROM YOUNG ESPGHAN

Niță AF, Hill CJ, Lindley RM,
Marven SS, Thomson MA

We report the case of a 9-year-old-girl with undiagnosed coeliac disease and Rapunzel syndrome who underwent endoscopic removal of a large trichobezoar, which was followed by unexpected multiple perforations of the small bowel and stomach. Argon plasma coagulation (APC) and snare electrocautery were employed during endoscopy to remove the trichobezoar piecemeal and approximately 70% was removed without any clear signs of damage to the mucosa. It was discovered subsequently that about 20 of her dolls were found without hair. On investigating the composition of a specific doll hair from the manufacturer, it was discovered that it could be hazardous if burned. It was therefore hypothesized that a constellation of factors had conspired to lead to perforation i.e. the potentially hazardous gas produced from the electrical energy applied to the synthetic hair and possible mucosal damage by the physical abrasion of this hair.

Take home message: before removal of a bezoar it is advisable to get detailed information of the material

References

1. A. Tringali, M. Thomson, JM. Dumonceau et al. Pediatric gastrointestinal endoscopy: European Society of Gastrointestinal Endoscopy (ESGE) and European Society for Paediatric Gastroenterology Hepatology and Nutrition (ESPGHAN) Guideline Executive summary. *Endoscopy* 2017; 49(01): 83-91
https://www.esge.com/assets/downloads/pdfs/guidelines/2016_s_0042_111002.pdf
2. Niță AF, Hill CJ, Lindley RM, Marven SS, Thomson MA. Human and Doll's Hair in a Gastric Trichobezoar, Endoscopic Retrieval Hazards. *J Pediatr Gastroenterol Nutr.* 2020 Aug;71(2):163-170

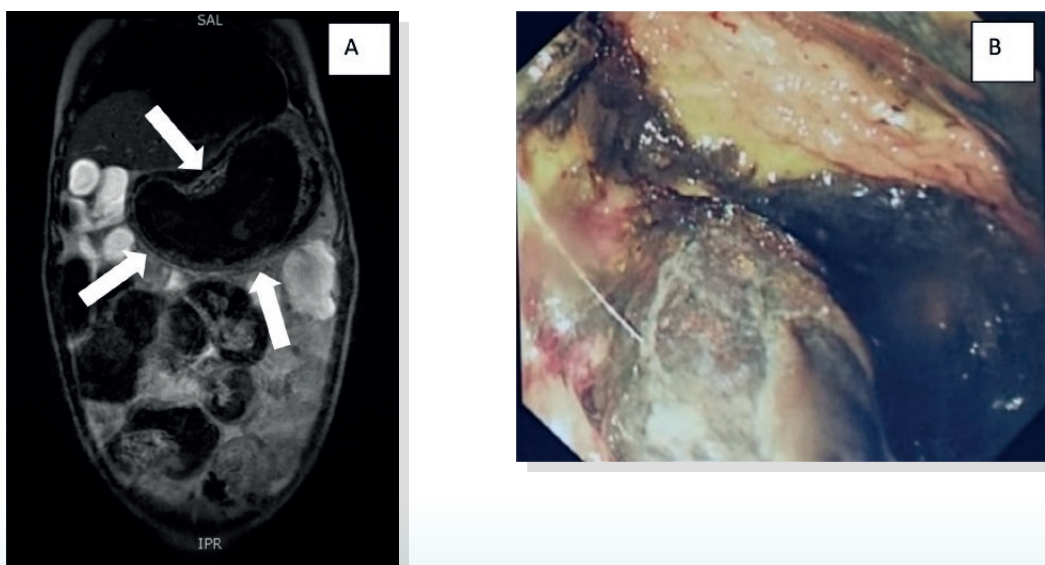


Figure 1

A. Trichobezoar on MRI – arrows pointing to the trichobezoar taking the shape of stomach.

B. Trichobezoar – endoscopic view