



IMAGE OF THE MONTH

05/2021

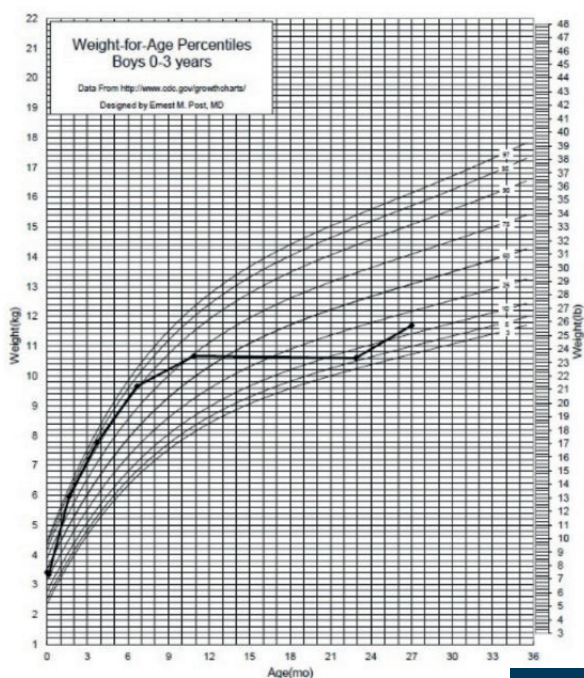
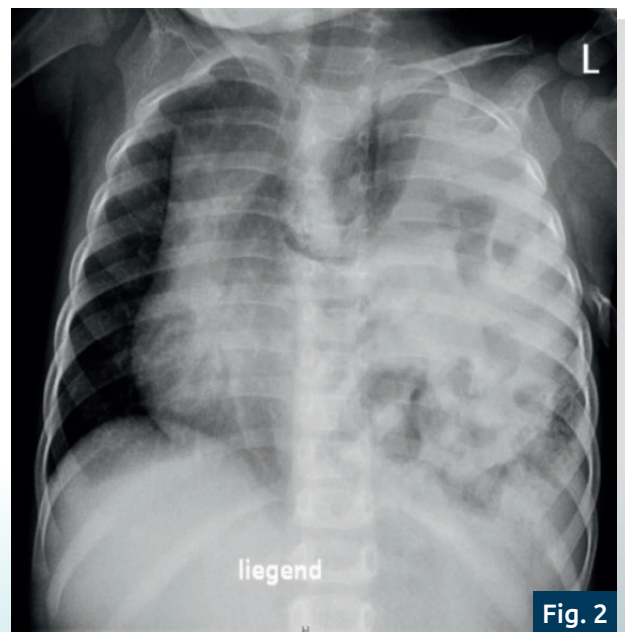
FROM YOUNG ESPGHAN

Dirk Nielsen
*Kinderklinik, Klinikum Kassel
Kassel, Germany*

Failure to thrive: A rare cause that can be heard

A 2-year-old boy was admitted to our clinic for further evaluation due to chronic coughing for 5 weeks. He was also vomiting at night every 2 weeks in the last 4 months. Besides known multiple food allergies and atopic dermatitis, a failure to thrive starting at about 8 months of age was noted (Figure 1). The patient was cared for by a paediatric pneumologist in an outpatient clinic and food provocation tests had been already performed. On clinical examination a slight protrusion of the sternum and weakened breath sounds on the left side of the lung were noted. There was no respiratory distress and no fever. The neurological examination was completely normal. Blood gas analysis and serum inflammatory markers on admission were unremarkable. Under the impression of a possible foreign body aspiration a plain chest X-ray was performed (Figure 2) which surprisingly showed a diaphragmatic hernia and an enterothorax on the left side with displacement of the mediastinum to the right side. In retrospect bowel sounds could be auscultated on the left side. The patient was then transferred to paediatric surgery for surgical correction.

In an enterothorax, parts of the gastrointestinal tract are displaced into the chest cavity by a diaphragmatic defect. Symptoms usually present short after birth with life-threatening respiratory distress and intestinal obstruction. However, delayed symptoms such as vomiting and failure to thrive with side-differentiated breathing sounds can occur as well. Despite increasingly economically optimised and engineered healthcare systems worldwide, a thorough clinical examination and trust in its results is still very important.

**Fig. 1****Fig. 2**